



PATIENT

Holly Hunt

SPECIES

Canine

BREED

Maltese

SEX

Female Spayed

AGE

10 years

WEIGHT

10.9lbs

INTERPRETED BY

Maggie Machen
Lamy, DVM
DACVIM (Cardiology)

IMAGING

PERFORMED BY

Pamela Harrigan,
RDCS

HOSPITAL NAME

Mass Veterinary
Services

REFERRING VET

Dr. Masloski

INVOICE

27713

DATE

11/30/22

PRESENTING CLINICAL SIGNS

History: Recheck echo. History chronic valvular disease - Stage B2. Presently, Holly's breathing is occasionally erratic. Moans when picked up. She was attacked by dogs in April and has not been the same since. Occasional cough; eating well. Painful hind end. On exam: NSR, grade III/VI murmur with PMI left apical area, PSS, lung fields clear. BP: 150 mmHg x 5. *No sedation for study. Current medications: 1) Pimobendan/vetmedin5mg 1/4 tab twice a day 2) Meloxicam as needed *No sedation for study.
-Pertinent previous echo findings (4/19/22 MML): LA 2.1 cm; LA:Ao 1.6; LV 2.3 cm; moderate LAE; moderate MR; moderate TR (2.7 m/s).

ECHOCARDIOGRAM FINDINGS

2D, m-mode, color flow and Doppler imaging is available.

Left ventricle: The LV diameter is normal with hyperdynamic function. LV wall thicknesses are normal.

Left atrium: The left atrium is mildly dilated.

Mitral valve: The mitral valve is diffusely thickened with prolapse into the left atrial lumen. Moderate eccentric mitral regurgitation with a normal velocity.

Aortic valve/Aorta: The aortic valve is normal in morphology and mobility. Normal aortic outflow velocity; laminar flow. No aortic insufficiency.

Right ventricle: Normal right ventricular diameter and morphology indicating no overt evidence of pulmonary arterial hypertension.

Right atrium: Normal RA dimension.

Tricuspid valve: The tricuspid valve appears thickened with septal prolapse and mild tricuspid regurgitation. Normal velocity.

Pulmonic valve/Pulmonary artery: The pulmonic valve is normal in morphology and mobility. No pulmonic insufficiency. Normal RVOT velocity; laminar flow.

Pericardium/other: No pericardial or pleural effusion noted. No obvious cardiac masses.

Heart rhythm: ECG reveals a sinus rhythm with an average HR of 150bpm.

2-Dimensional Measurements

Ao diam (cm)	1.3
LA diam (cm)	2.0
LA:Ao (Swe)	1.5
IVS thickness (cm)	0.6
LVID diastole (cm)	2.2
PW thickness (cm)	0.6
LVID systole (cm)	0.9
FS (%)	59

Doppler Measurements

PV Vmax (m/s)	1.2
AoV Vmax (m/s)	1.7
MR Vmax (m/s)	5.8
TR Vmax (m/s)	2.4
TR PG (mmHg)	24

INTERPRETATION OF THE FINDINGS

Chronic degenerative valve disease persists with evidence of slight improvement on Pimobendan. Moderate mitral and mild tricuspid regurgitation appear stable with improved left heart dimensions. No additional issues are identified.

Given these findings, continue Pimobendan is recommended as below. Assessment of progression in the future will help predict long term outcome, however prognosis is guarded at this stage (B2).



PATIENT

Holly Hunt

SPECIES

Canine

BREED

Maltese

SEX

Female Spayed

AGE

10 years

WEIGHT

10.9lbs

INTERPRETED BY

Maggie Machen
Lamy, DVM
DACVIM (Cardiology)

**IMAGING
PERFORMED BY**

Pamela Harrigan,
RDCS

HOSPITAL NAME

Mass Veterinary
Services

REFERRING VET

Dr. Masloski

INVOICE

27713

DATE

11/30/22

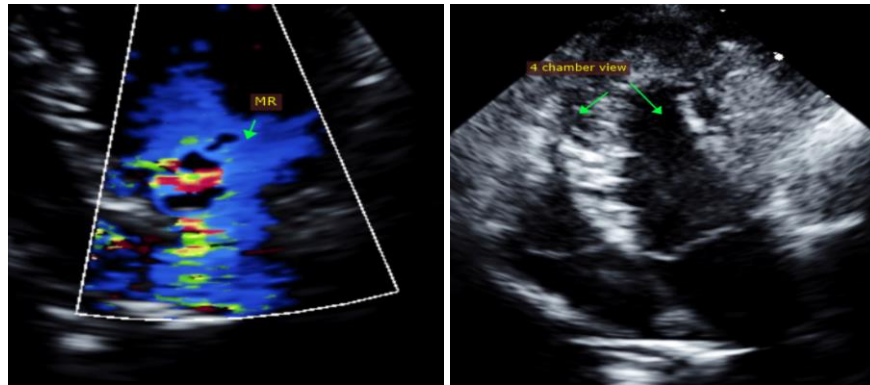
RECOMMENDATIONS

- Continue Pimobendan 0.3mg/kg PO q12h.
- Omega fatty acid supplementation and mild salt restriction may be of some long-term benefit.
- Anesthetic risk is considered mild if needed. Cardiac protective drug choices (opioid/benzodiazepine premedication, propofol or alfaxalone induction, isoflurane gas) are recommended. Pre-oxygenate for 5-10 minutes prior to induction. Monitor for arrhythmias, hypotension, and hypoxia both intra and post-operatively and intervene as necessary. Mild IV fluid restriction is recommended to avoid fluid overload. Avoid heart rate stimulating drugs such as atropine unless clinically indicated.
- Monitor for development of a cough, labored breathing, exercise intolerance or collapse episodes.

PLAN

- Recommend conservative monitoring with a recheck echocardiogram in 6-8 months, sooner if any development of clinical signs.

IMAGES



The information and recommendations provided are based on the images presented by the referring veterinarian. No evaluation can be communicated regarding pathology that was not visible in the image/video clips provided.

Thank you for this referral. This report was generated using transcription software, and minor dictation errors may be present. If the clinical or image interpretation does not parallel your findings or if I can be of any further assistance, please contact me.

Maggie Machen Lamy, DVM
Diplomate of the American College of Veterinary Internal Medicine (Cardiology)
info@sonopath.com

Echocardiogram performed by:

Pamela Harrigan, RDCS
Pet Animal Ultrasound Service (4paus.com)